

EDRST 2359049  
7  
Povirus

1

APPARENT MODE  
**HOMICIDE**

CASE NO  
2014-05570

SPECIAL CIRCUMSTANCES  
Gunshot Wound, Media Interest, Officer Involved

CRYPT  
13

LAST, FIRST MIDDLE

**FORD, EZELL EARL**

AKA

#

ADDRESS

352 66TH STREET

CITY

LOS ANGELES

STATE

CAL

ZIP

90003

SEX	RACE APPEARS	DOB	AGE	HGT	WGT	EYES	HAIR	TEETH	FACIAL HAIR BEARD AND MUSTACHE	ID VIEW	CONDITION
MALE		#####	25	73 in.	171 lbs.	BROWN	BLACK	ALL NATURAL TEETH		Yes	FAIR

MARK TYPE	MARK LOCATION	MARK DESCRIPTION
TATTOO	CHEST	
TATTOO	FOREHEAD	
TATTOO	BOTH HANDS	

NOK

NOTIFIED BY

DATE

TIME

8/11/2014 22:10

PENDING BY

ID METHOD

FINGERPRINTS FROM DOJ

LA #	MAIN #	CII #	FBI #	MILITARY #	POB
	32606402	A26450795	177968JC0		CALIFORNIA

IDENTIFIED BY NAME (PRINT)

RELATIONSHIP

PHONE

DATE

TIME

CALPHOTO

8/13/2014 16:21

PLACE OF DEATH / PLACE FOUND

ADDRESS OR LOCATION

CITY

ZIP

HOSPITAL

1401 S GRAND AVENUE

LOS ANGELES

90015

CALIFORNIA MEDICAL CENTER

PLACE OF INJURY

AT WORK

DATE

TIME

LOCATION OR ADDRESS

ZIP

SIDEWALK

No

8/11/2014

20:10

240 W. 65TH STREET, LOS ANGELES, CA

90003

DOD

TIME

FOUND OR PRONOUNCED BY

DR. HUBBARD

OTHER AGENCY INV. OFFICER

PHONE

REPORT NO.

NOTIFIED BY

NO

LAPD FORCE INVESTIGATION DIV - DET SOLORZ (213) 486-5286

F047-14

TRANSPORTED BY

LOS ANGELES FSC

DATE

TIME

GABRIEL MARTINEZ

8/13/2014 15:02

FINGERPRINTS?	Yes	CLOTHING	Yes	PA RPT	No	MORTUARY	
MED. EV.	No	INVEST. PHOTO #	1	SEAL TYPE	NOT SEALED	HOSP RPT	Yes
PHYS. EV.	Yes	EVIDENCE LOG	Yes	PROPERTY?	No	HOSP CHART	Yes
SUICIDE NOTE	No	GSR NO	C9265	RCPT. NO.	275574	PF NO.	10181241

SYNOPSIS

THE DECEDENT IS A MALE, AFRICAN AMERICAN, 25 YEARS OF AGE, ACCORDING TO POLICE, POLICE OFFICERS ATTEMPTED TO DETAIN THE DECEDENT WHEN HE BECAME PHYSICAL AND ATTEMPTED TO REACH FOR AN OFFICERS WEAPON WHEN HE WAS REPORTEDLY SHOT BY POLICE. 2 GSW RIGHT ARM & RIGHT BACK - EXPIRED AT CALIFORNIA HOSPITAL

ALLEN R. MOSES

298382

INVESTIGATOR

DATE

8/13/2014

TIME

23:02

REVIEWED BY

DATE

8/13/14

TIME

FORM #3 NARRATIVE TO FOLLOW?



County of Los Angeles, Department of Coroner  
Investigator's Narrative



Case Number: CaseNum 2014-05570 Decedent: FullName FORD, EZELL EARL

---

**Information Sources:**

1. Meg Datu – Nursing Supervisor – California Hospital  
1401 S. Grand Avenue, Los Angeles, CA 90015

**Investigation:**

On 08/12/2014 at 1515 hours Meg Datu, Nursing Supervisor from California Hospital reported this case as a homicide to the Los Angeles County Department of Medical Examiner / Coroner, reporting desk, receipt by Christopher Matheu. Hospital case.

**Location:**

Place of death: California Hospital 1401 S. Grand Avenue, Los Angeles, CA 90015

**Informant/Witness Statements:**

According to information provided by the hospital, on Monday 08/11/2014 at approximately 2010 hours Police Officers attempted to detain the decedent who reportedly became physical with them and attempted to reach for one of the Police Officer's weapons at which time he was shot. The incident took place on a sidewalk located at 240 W. 65<sup>th</sup> Street, Los Angeles 90003. Los Angeles City Fire Department paramedics RA033 responded to the scene location and transported the decedent to California Hospital 1401 S. Grand Avenue, Los Angeles 90015 where he remained until he expired Monday 08/11/2014 at 2210 hours, pronounced by Dr. Hubbard. No further information was provided. This incident is being investigated by Detective Robert Solorza #2773 from the Los Angeles Police Department Force Investigation Division.

**Scene Description:**

No Coroner scene investigation.

**Evidence:**

On 08/13/2014 Gabriel Martinez, Forensic Attendant collected a hair standards kit at 1547 hours and a gunshot residue kit C9265 at 1530 hours.

**Body Examination:**

On 08/13/2014 I performed the initial external body exam of the decedent at the Forensic Science Center, refrigerator, the decedent was observed lying in a supine position on a small table in the receiving processing room. The decedent is a male, African American, who appears to be the reported 25 years of age. The decedent presents with short curly brown hair, brown eyes, beard & moustache, and natural teeth.

The decedent was transported from California Hospital on Wednesday 08/13/2014 to the Forensic Science Center at 1502 hours, and processed into the facility at 1610 hours by Gabriel Martinez, Forensic Attendant. At the time of processing the decedent was recorded with a height of 73 inches and a weight of 171 pounds.



County of Los Angeles, Department of Coroner  
Investigator's Narrative



Case Number: CaseNum 2014-05570

Decedent: FullName FORD, EZELL EARL

Medical appliances consisted of NGT, ETT, right lateral jugular central line, left lateral chest tube, disposable defibrillator pads, foley catheter, IV line to the left forearm, and bilateral lower extremity pressure wraps. The decedent has tattoos noted to the forehead, chest, and both hands. There are healed scars to the posterior surface of the right hand. The decedent has what appears to be gunshot wounds to the upper right arm possibly and right back, and another gunshot wound to the right abdomen. Abrasions noted to the posterior surface of the left hand, forearm, and elbow. There were no other marks, scars, tattoos, deformities, or trauma noted.

**Identification:**

CALPHOTO CDL E1465953. DOJ AFIS.

**Next of Kin Notification:**

**Tissue Donation:**

The decedent is not a viable candidate for tissue donation due to the time lapse since he expired on Monday 08/11/2014 at 2210 hours at California Hospital.

**Autopsy Notification:**

See case notes.

Investigator's Name

Supervisor's Name

08/13/2014

Date of Report

**12****AUTOPSY REPORT**

No.

2014-05570

FORD, EZELL EARL

I performed an autopsy on the body of →

at \_\_\_\_\_ the DEPARTMENT OF CORONER

Los Angeles, California

on AUGUST 14, 2014 @ 1100 HOURS  
(Date) (Time)From the anatomic findings and pertinent history I ascribe the death to:(A) **MULTIPLE GUNSHOT WOUNDS**

DUE TO OR AS A CONSEQUENCE OF

(B)

DUE TO OR AS A CONSEQUENCE OF

(C)

DUE TO OR AS A CONSEQUENCE OF

(D)

OTHER CONDITIONS CONTRIBUTING BUT NOT RELATED TO THE IMMEDIATE CAUSE OF DEATH

*Anatomic Summary:*

The decedent was a 25-year-old Black male who was shot during an altercation with police officers. He was transported to the hospital. Right thoracotomy with partial right lung resection, exploratory laparotomy, with transverse colon resection and repair of inferior vena cava bleed was done. He died in the operating room.

Gunshot wounds are numbered from front to back.

I. Gunshot wound #1, fatal gunshot wound of right flank:

- A. The entrance wound is round shaped and measures 3/8 of an inch. The entrance wound is situated at the right flank/abdomen 26 inches from top of the head and 5 inches right from midline. Soot or stippling is not present. The surrounding skin has 1/16 of an inch abrasion.
- B. There is no exit wound.
- C. The projectile was recovered from the lumbar vertebra #3 and submitted for evidence.
- D. The direction of the wound is front to back, right to left, downwards.
- E. The wound path enters through the skin, right rib #9 lateral/anterior, liver, colon, mesentery, inferior vena cava, terminating in the lumbar vertebra #3.
- F. Associated injury: Hemoperitoneum.

**12****AUTOPSY REPORT**

No.

2014-05570

FORD, EZELL EARL

Page 2

## II. Gunshot wound #2, fatal gunshot wound of right back:

- A. The entrance wound is round shaped and measures 1/2 of an inch. The entrance wound is situated at the right back 18 inches from top of the head and 4-1/2 inches right of the midline. The surrounding skin has muzzle imprint measuring 1-1/4 of an inch.
- B. The exit wound is incorporated into right thoracotomy wound.
- C. No projectile was recovered at the autopsy.
- D. The direction of the wound is back to front and slightly left to right.
- E. The wound path enters through the skin, right rib #9 posterior with fracture, right lung, right rib #6 anterior with fracture.
- F. Associated injury: Right hemothorax.

## III. Gunshot wound #3, nonfatal gunshot wound of right arm:

- A. The entrance wound is round shaped and measures 3/8 of an inch. The entrance wound is situated at the right arm posterior/lateral surface 3 inches above the elbow. Soot or stippling is not present. The surrounding skin has 1/16 of an inch abrasion.
- B. The partial exit wound is stellate shaped and measures 1/4 of an inch. The wound exit is situated at the right arm posterior/medial surface 3 inches above the elbow and 3 inches from the entry.
- C. The fragmented projectile was recovered from the right arm and submitted for evidence.
- D. The direction of the wound is right to left and slightly front to back.
- E. The wound path enters through the skin, right distal humerus with fracture.

## EXTERNAL EXAMINATION:

The body is identified by toe tags and is that of an unembalmed, refrigerated adult Black male who appears about the reported age of 25 years. The body weighs 171 pounds, measures 73 inches and is well built. Multiple tattoos are noted. Please see

**12****AUTOPSY REPORT**

No.

2014-05570

FORD, EZELL EARL

Page 3

autopsy photographs. There is vague abrasion in the right abdomen lower measuring 3 x 1/4 of an inch. There are small scars in the right knee area. There are small abrasions in the left elbow area. There is abrasion on top of left shoulder measuring 1 x 1/4 of an inch. Rigor mortis has presumably been altered.

The head is normocephalic and covered by short black hair. There is no balding. Short mustache and beard are present. Examination of the eyes reveals irides that appear to be brown in color and sclera that are white. There are no petechial hemorrhages. Upper and lower teeth are present. The neck is unremarkable. There is no chest deformity. The abdomen is flat. The genitalia are without trauma or lesions.

**EVIDENCE OF THERAPEUTIC INTERVENTION:**

The following are present and are in proper position: Endotracheal tube, nasogastric tube, intravenous line. There is sutured laparotomy wound and sutured right thoracotomy wound. There is left chest tube.

**CLOTHING:**

The body was not clothed and the clothing was not available at the time of the autopsy.

**INITIAL INCISION:**

The body cavities are entered through the standard coronal and the standard Y-shaped incisions. Additional incisions are made in right arm area in order to recover fragmented projectile.

**NECK:**

The neck organs are removed en bloc with the tongue. There are no lesions to the lips or oral mucosa. Both hyoid bone and larynx are intact and without fractures. There is no hemorrhage

**12****AUTOPSY REPORT**

No.

2014-05570

FORD, EZELL EARL

Page 4

in the neck muscles or thyroid. The tongue when sectioned shows no trauma.

**CHEST/ABDOMINAL CAVITY:**

The right pleural cavity contains 750 cc of dark blood. Soft tissues of the thoracic and abdominal walls are well preserved. The subcutaneous fat of the abdominal wall measures 1 inch. There is blood collection in the peritoneal cavity, small amount.

**CARDIOVASCULAR SYSTEM:**

The aorta is fairly elastic. There are sutures in the inferior vena cava adjacent to the gunshot wound track in the abdomen. Pericardium has been previously opened. The weight of the heart is 360 grams. It has a normal configuration. The valves are unremarkable. The myocardium is grossly unremarkable. The coronary arteries have no significant atherosclerosis. There is a small amount of blood within the heart and large blood vessels.

**RESPIRATORY SYSTEM:**

Bloody fluid is found in trachea and bronchi. The weight of the right lung is 390 grams. The weight of the left lung is 400 grams. There is evidence of right lower lung partial resection with sutures. Parenchyma of the lungs otherwise appears unremarkable. The pulmonary vasculature is without thromboembolism.

**GASTROINTESTINAL SYSTEM:**

The esophagus is intact. The stomach contains a few cc of food and mucus. Portions of tablets or capsules cannot be found in the stomach. There appears to be partial resection of colon with sutures. The small intestine appears grossly unremarkable. The pancreas is unremarkable. The appendix is present.

**12****AUTOPSY REPORT**

No.

2014-05570

FORD, EZELL EARL

Page 5

## HEPATOBIILIARY SYSTEM:

The liver weighs 1560 grams. There is a gunshot wound through the anterior edge of the liver, stellate shaped, measures 2 inches. The parenchyma of the liver is otherwise unremarkable. The gallbladder contains a few cc of bile and no calculi.

## URINARY SYSTEM:

The left kidney weighs 150 grams. The right kidney weighs 150 grams. The parenchyma of the kidneys is grossly unremarkable. The urinary bladder is empty.

## GENITAL SYSTEM (MALE):

The prostate is unremarkable. Both testes are in the scrotum and without trauma.

## HEMOLYMPHATIC SYSTEM:

The spleen weighs 110 grams. The capsule is intact. The parenchyma is grossly unremarkable. Lymph nodes throughout the body are small and inconspicuous. The bone and the bone marrow of the rib is grossly unremarkable.

## ENDOCRINE SYSTEM:

The thyroid gland, adrenal glands, pituitary gland are unremarkable. The thymus is unremarkable for the age.

## HEAD AND CENTRAL NERVOUS SYSTEM:

There is no hemorrhage in the skull. There are no fractures of the scalp. There is no epidural, subdural or subarachnoid hemorrhage. The brain weighs 1280 grams. The leptomeninges are thin and transparent. A normal convolutionary pattern is observed. Coronal sectioning demonstrates a uniformity of



**12****AUTOPSY REPORT**

No.

2014-05570

FORD, EZELL EARL

Page 6

cortical gray thickness. The cerebral hemispheres are symmetrical. There is no softening, discoloration or hemorrhage of the white matter. The basal ganglia are intact. Anatomic landmarks are preserved. Cerebral contusions are not present. The ventricular system is unremarkable. Pons, medulla and cerebellum are unremarkable. There is no evidence of herniation. The cerebral arteries have no significant atherosclerosis.

**SPINAL CORD:**

The spinal cord was not dissected.

**HISTOLOGIC SECTIONS:**

Representative sections from various organs are preserved in one storage jar in 10% formalin.

**TOXICOLOGY:**

EDTA blood, femoral blood, chest blood, stomach contents, and vitreous have been submitted to the lab. A homicide screen was requested.

**PHOTOGRAPHY:**

Photographs have been taken prior to and during the course of the autopsy.

**RADIOLOGY:**

The body is fluoroscoped and multiple x-rays are taken. The x-rays show a fragmented projectile in the right arm area and an intact projectile in the lumbar vertebra.

**12****AUTOPSY REPORT**

No.

2014-05570

FORD, EZELL EARL

Page 7

## WITNESSES:

LAPD Detective Granados, LAPD Criminalist Alvarado and Garcia,  
and Dr. Fajardo witnessed the autopsy.

## DIAGRAMS USED:

Diagram Forms #16, 20, 52 were used during the performance of the  
autopsy.

## OPINION:

Dr. Fajardo and Dr. Wang were consulted for gunshot wound  
appearance and they concur that the right back wound has muzzle  
imprint.



VADIMS POUKENS, M.D.  
DEPUTY MEDICAL EXAMINER

9/23/14  
DATE

VP:mtm:f  
D: 8/14/14  
T: 8/20/14

15

AUTOPSY CLASS:  A  B  C  Examination Only D

FAMILY OBJECTION TO AUTOPSY

Date: 8/14/14 Time: 1100 Dr. Poukens  
(Print)

FINAL ON: 8/14/14 By: Poukens  
(Print)

APPROXIMATE INTERVAL BETWEEN ONSET AND DEATH:

2014-05570  
FORD, EVELL  
NONE

13

DEATH WAS CAUSED BY: (Enter only one cause per line for A, B, C, and D)

IMMEDIATE CAUSE:

(A) Multiple gunshot wounds

DUE TO, OR AS A CONSEQUENCE OF:

(B)

DUE TO, OR AS A CONSEQUENCE OF:

(C)

DUE TO, OR AS A CONSEQUENCE OF:

(D)

OTHER CONDITIONS CONTRIBUTING BUT NOT RELATED TO THE IMMEDIATE CAUSE OF DEATH:

Age: 25 Gender: Male Female

PRIOR EXAMINATION REVIEW BY DME

BODY TAG A S  CLOTHING  
 X-RAY (No.         )  FLUORO  
 SPECIAL PROCESSING TAG  MED. RECORDS  
 AT SCENE PHOTOS (No.         )

CASE CIRCUMSTANCES

EMBALMED  
 DECOMPOSED  
 >24 HRS IN HOSPITAL  
 OTHER:          (Reason)

TYPING SPECIMEN

TYPING SPECIMEN TAKEN BY:           
SOURCE: Chest

TOXICOLOGY SPECIMEN

COLLECTED BY:           
 HEART BLOOD  STOMACH CONTENTS  
 FEMORAL BLOOD  VITREOUS  
TECHNIQUE: Chest BLOOD  SPLEEN  
 BILE BLOOD  KIDNEY  
 LIVER            
 URINE          

URINE GLUCOSE DIPSTICK RESULT: 4+ 3+ 2+ 1+ 0  
TOX SPECIMEN RECONCILIATION BY: A S

HISTOLOGY

Regular (No. 1)  Oversize (No.         )  
Histopath Cut:  Autopsy  Lab

TOXICOLOGY REQUESTS

FORM 3A:  YES  NO  
 NO TOXICOLOGY REQUESTED  
SCREEN  C  H  T  S  D  
 ALCOHOL ONLY  
 CARBON MONOXIDE  
 OTHER (Specify drug and tissue)

REQUESTED MATERIAL ON PENDING CASES

POLICE REPORT  MED HISTORY  
 TOX FOR COD  HISTOLOGY  
 TOX FOR R/O  INVESTIGATIONS  
 MICROBIOLOGY  EYE PATH. CONS.  
 RADIOLOGY CONS.  
 CONSULT ON:  
 BRAIN SUBMITTED  
 NEURO CONSULT  DME TO CUT  
 CRIMINALISTICS  
 GSR  SEXUAL ASSAULT  OTHER

NATURAL  SUICIDE  HOMICIDE  
 ACCIDENT  COULD NOT BE DETERMINED

If other than natural causes, HOW DID INJURY OCCUR? shot by officer(s) during altercation

WAS OPERATION PERFORMED FOR ANY CONDITION STATED ABOVE:  YES  NO

TYPE OF SURGERY:          DATE: 8/14/14

ORGAN PROCUREMENT  TECHNICIAN: Robina  
PREGNANCY IN LAST YEAR  YES  NO  UNK  NOT APPLICABLE

WITNESS TO AUTOPSY  EVIDENCE RECOVERED AT AUTOPSY  
Item Description:

2 projectiles

thoracotomy / laparotomy

LAPD det. R. Granada  
criminalist K. Alvarado

R. Garcia

Dr. Fajardo

[Signature]

RESIDENT

DME

16

2014-05570  
FORD, EZELL  
HONI

13

EXTERNAL EXAM

- Sex
- Race
- Age
- Height
- Weight
- Hair
- Eyes
- Sclera
- Teeth
- Mouth
- Tongue
- Nose
- Chest
- Breasts
- Abdomen
- Scar
- Genitals
- Edema
- Skin
- Decubitus

HEART Wt. 360

- Pericardium - open RV
- Hypertrophy Septum
- Dilation LV
- Muscle Septum
- Valves
- Coronaries

AORTA

VESSELS

LUNGS Wt. 390 resected w/ sutures  
400

- R
- L
- Adhesions
- Fluid
- Atelectasis
- Oedema
- Congestion
- Consolidation
- Bronchi
- Nodes

PHARYNX

TRACHEA

THYROID

THYMUS

LARYNX

HYOID

ABDOMINAL WALL FAT 1"

PERITONEUM

- Fluid
- Adhesions

LIVER Wt. 156g

- Capsule
- Lobules
- Fibros
- G B
- Calculus
- Bile ducts

SPLEEN Wt. 110

- Color
- Consistency
- Capsule
- Malpiment

PANCREAS

ADRENALS

KIDNEYS Wt. 150

- R
- L
- Capsule
- Cortex
- Vessels
- Pelvis
- Ureters

BLADDER

GENITALIA

- Prostate
- Testes
- Uterus
- Tubes
- Ovaries

OESOPHAGUS

STOMACH

- Contents

DUOD. & SM. INT.

APPENDIX

LARGE INT. + 12 side resect. sutures

ABDOM. NODES

SKELETON

- Spine
- Marrow
- Rib Cage
- Long bones
- Pelvis

SCALP

CALVARIUM

BRAIN Wt. 1280

- Dura
- Fluid
- Ventricles
- Vessels
- Middle ears
- Other

PITUITARY

SPINAL CORD

TOXICOLOGY SPECIMENS

SECTIONS FOR HISTOPATHOLOGY

MICROBIOLOGY

DIAGRAMS  
X-RAYS

OTHER PROCEDURES

GROSS IMPRESSIONS

Date

8/14/14

Time

1100

Deputy Medical Examiner

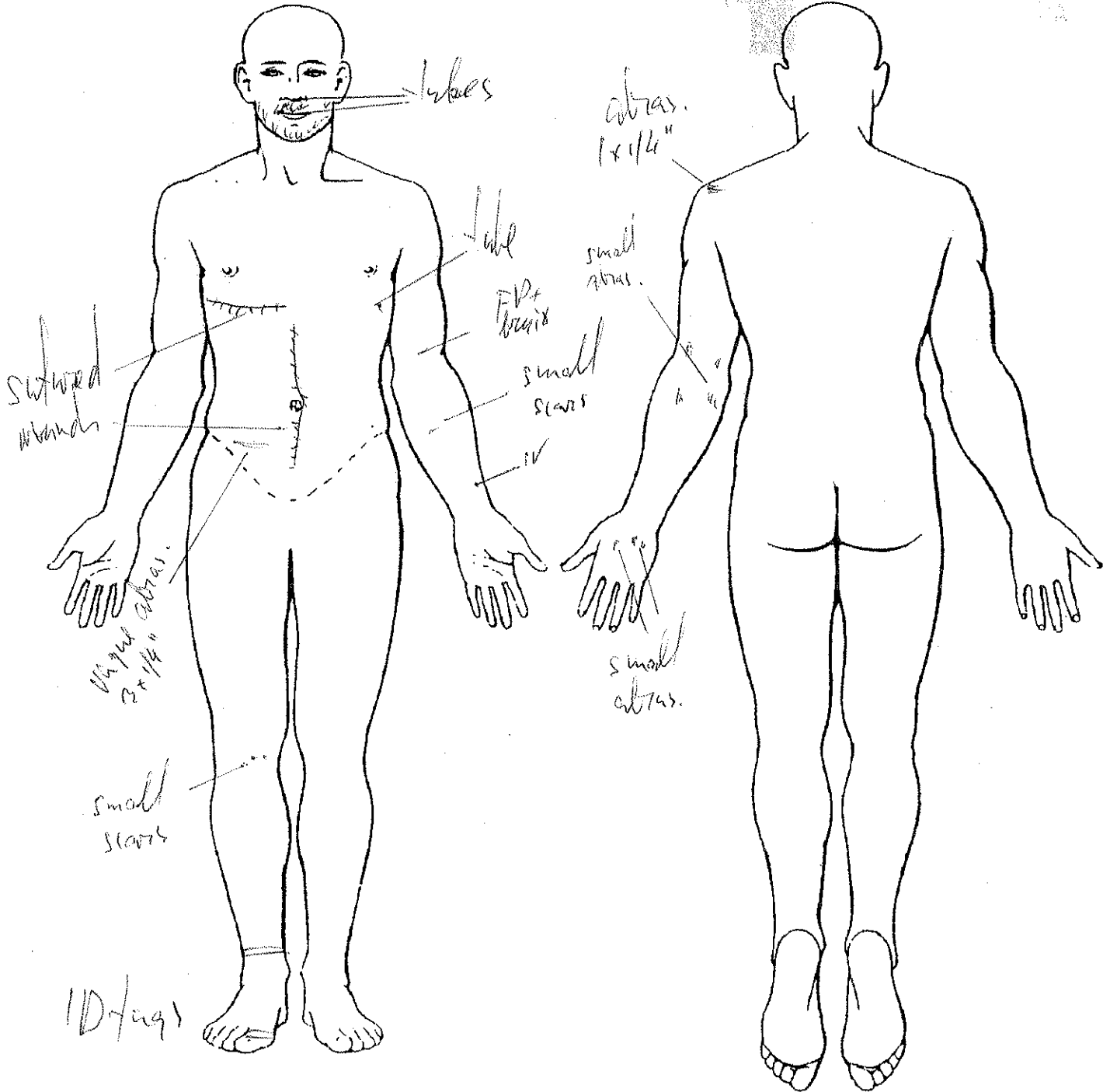
*[Signature]*

20

Black ♂  
multiple tattoos

2014-05570  
FORD, EZELL  
HOMI

13



Date 8/14/14

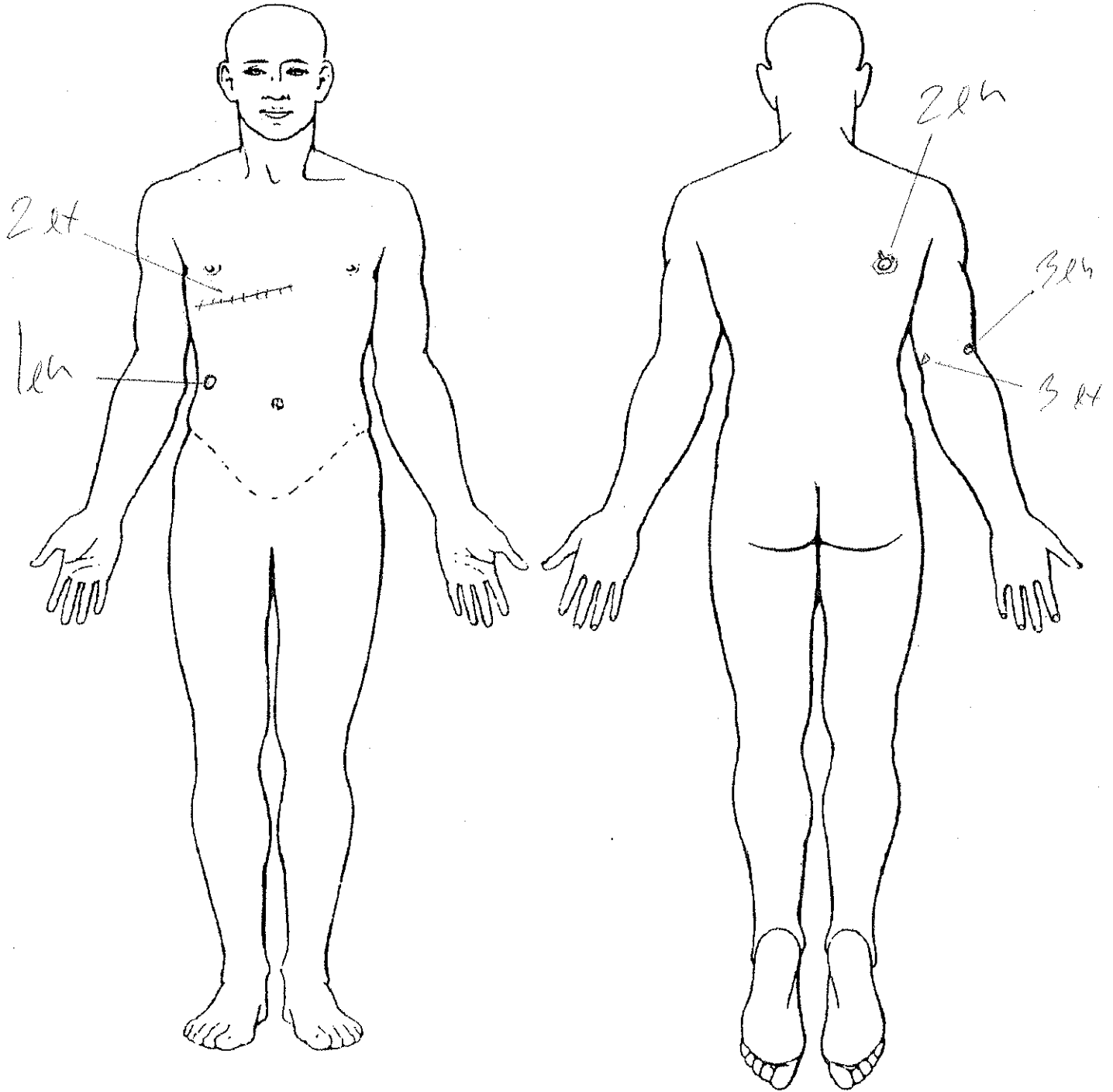
*[Signature]* M.D.  
Deputy Medical Examiner

20

9 SW  
lh - entry  
rt - exit

2014-05570  
FORD, EZELL  
HOMI

13



Date

8/14/14

*[Signature]*

M.D.

Deputy Medical Examiner



# GUNSHOT WOUND

07220-4105

11353 .CR03

The direction of the wound is <sup>MOH</sup> E I

<input type="checkbox"/> back to front
<input checked="" type="checkbox"/> front to back
<input type="checkbox"/> left to right
<input checked="" type="checkbox"/> right to left
<input checked="" type="checkbox"/> downwards
<input type="checkbox"/> upwards

The wound path penetrates through the skin / mucosa of the

R rib # 9 lat/ant,

<input type="checkbox"/> completely disrupts
<input type="checkbox"/> penetrates
<input type="checkbox"/> perforates

the liver, colon, mesentery, IVC

and penetrates into the \_\_\_\_\_ terminating at the L#3 vertebra

X-rays are taken of the following areas: \_\_\_\_\_

and show \_\_\_\_\_

Diagrams used: \_\_\_\_\_

Photographs obtained:

<input type="checkbox"/> at scene
<input type="checkbox"/> during examination

## OPINION

This wound is

<input type="checkbox"/> immediately life threatening
<input type="checkbox"/> not immediately life threatening

due to

<input type="checkbox"/> hemorrhage of _____
<input checked="" type="checkbox"/> the perforated <u>liver, colon, IVC</u>

Assoc. inj.: hemo peri to heart

[Signature]

8/14/14



52

GUNSHOT WOUND # 2

FOLLOW FORM EXACTLY AS PRINTED  
CIRCLE OR CHECK ONE OR THOSE THAT APPLY  
REMEMBER THE FORM IS PRINTED ON BOTH SIDES

2014-05570  
FORD, EZEEL  
H011

13

page 1 of 2

fatal, R back

The **entrance** wound is

○ shaped and measures 1/2 inches

The entrance wound is situated at the

18" TORN 4 1/2" R ON R back

is centered \_\_\_\_\_ inches from the vertex / external auditory meatus

and \_\_\_\_\_ inches to the left / right of midline.

Sooting

is present and measures \_\_\_\_\_ inches.  
 is not

A muzzle imprint is

present  
 absent

1 1/4"

Stippling and / or tattooing can be described as \_\_\_\_\_

and the spread measures \_\_\_\_\_ inches. The surrounding skin \_\_\_\_\_

There is no exit wound

OR

incorporated into R thoraxotomy wound

The **exit** wound is

\_\_\_\_\_ shaped and measures \_\_\_\_\_ inches

The wound exit is situated at the

is centered \_\_\_\_\_ inches from the vertex / external auditory meatus

and \_\_\_\_\_ inches to the left / right of midline.

It is oriented

diagonal  
 parallel  
 perpendicular

to the long axis of the body.

No **projectile** was recovered at autopsy.

The projectile was recovered from the \_\_\_\_\_

and  submitted for evidence or

released to the evidence custodian.

It is described as: \_\_\_\_\_

# GUNSHOT WOUND

07220-#105

JJ319 .0803

The direction of the wound is

<input checked="" type="checkbox"/> back to front
<input type="checkbox"/> front to back
<input checked="" type="checkbox"/> left to right
<input type="checkbox"/> right to left
<input type="checkbox"/> downwards
<input type="checkbox"/> upwards

The wound path penetrates through the skin /mucosa of the

<input type="checkbox"/> completely disrupts
<input type="checkbox"/> penetrates
<input type="checkbox"/> perforates

*R rib # 9 post c of p*  
the *R lung*, *R rib # 6 ant v of p*

and penetrates into the \_\_\_\_\_ terminating at the \_\_\_\_\_

X-rays are taken of the following areas: \_\_\_\_\_

and show \_\_\_\_\_

Diagrams used: \_\_\_\_\_

Photographs obtained:

<input type="checkbox"/> at scene
<input type="checkbox"/> during examination

## OPINION

This wound is

<input type="checkbox"/> immediately life threatening
<input type="checkbox"/> not immediately life threatening

due to

<input type="checkbox"/> hemorrhage of _____
<input checked="" type="checkbox"/> the perforated <i>lung</i>

*Assoc. inj. : R hemothorax*

*R. Viner*

52

GUNSHOT WOUND # 3

FOLLOW FORM EXACTLY AS PRINTED  
CIRCLE OR CHECK ONE OR THOSE THAT APPLY  
REMEMBER THE FORM IS PRINTED ON BOTH SIDES

2014-05570  
FORD, EZELL  
HONI

13

page 1 of 2

non-fatal, R arm

The entrance wound is

0 shaped and measures 3/8 inches

The entrance wound is situated at the

R arm  
port/hat 3" 9" elbow

is centered \_\_\_\_\_ inches from the vertex / external auditory meatus

and \_\_\_\_\_ inches to the left / right of midline.

Sooting

is  
 is not

present and measures \_\_\_\_\_ inches.

A muzzle imprint is

present  
 absent

Stippling and / or tattooing can be described as \_\_\_\_\_

and the spread measures \_\_\_\_\_ inches. The surrounding skin \_\_\_\_\_

1/16" abs.

There is no exit wound

OR

partial  
The exit wound is

S-Icclate shaped and measures 1/4 inches

The wound exit is situated at the

R arm  
port/hat 3" 9" elbow  
and 3" from entry

is centered \_\_\_\_\_ inches from the vertex / external auditory meatus

and \_\_\_\_\_ inches to the left / right of midline.

It is oriented

diagonal  
 parallel  
 perpendicular

to the long axis of the body.

fragmented

No projectile was recovered at autopsy.

The projectile was recovered from the

R arm

and  submitted for evidence or

It is described as: \_\_\_\_\_

released to the evidence custodian.

# GUNSHOT WOUND

07220-4105

11353 .0807

The direction of the wound is

el

<input type="checkbox"/> back to front
<input checked="" type="checkbox"/> front to back
<input type="checkbox"/> left to right
<input checked="" type="checkbox"/> right to left
<input type="checkbox"/> downwards
<input type="checkbox"/> upwards

slightly

The wound path penetrates through the skin / mucosa of the

R distal humerus

<input type="checkbox"/> completely disrupts
<input type="checkbox"/> penetrates
<input type="checkbox"/> perforates

the \_\_\_\_\_

and penetrates into the \_\_\_\_\_ terminating at the \_\_\_\_\_

X-rays are taken of the following areas: \_\_\_\_\_

and show \_\_\_\_\_

Diagrams used: \_\_\_\_\_

Photographs obtained:

<input type="checkbox"/> at scene
<input type="checkbox"/> during examination

## OPINION

This wound is

<input type="checkbox"/> immediately life threatening
<input checked="" type="checkbox"/> not immediately life threatening

due to

<input type="checkbox"/> hemorrhage of _____
<input type="checkbox"/> the perforated _____

*[Signature]*

8/14/14



Department of Medical Examiner-Coroner, County of Los Angeles

**FORENSIC SCIENCE LABORATORIES**

1104 North Mission Road Los Angeles, CA 90033



**Laboratory Analysis Summary Report**

Poukens, Vadims M.D.

Deputy Medical Examiner  
1104 North Mission Road  
Los Angeles, CA 90033

PendingTox

The following results have been technically and administratively reviewed and are the opinions and conclusions of the Analyst:

**Coroner Case Number:** 2014-05570    **Decedent:** FORD, EZELL EARL

<u>SPECIMEN</u>	<u>SERVICE</u>	<u>DRUG</u>	<u>RESULT</u>	<u>ANALYST</u>
Blood, Chest				
	Alcohol-GC/FID-HS	Ethanol	Negative	E. Fu
	Bases-GC/NPD &/or MS	Basic Drugs	ND	E. Fu
	ELISA-Immunoassay	Barbiturates	ND	B. Ciullo
	ELISA-Immunoassay	Cocaine and Metabolites	ND	B. Ciullo
	ELISA-Immunoassay	Fentanyl	ND	B. Ciullo
	ELISA-Immunoassay	Marijuana:11-nor-Delta-9-Carboxy-THC	PP	B. Ciullo
	ELISA-Immunoassay	Methamphetamine & MDMA	ND	B. Ciullo
	ELISA-Immunoassay	Opiates: Codeine & Morphine	ND	B. Ciullo
	ELISA-Immunoassay	Opiates: Hydrocodone & Hydromorphone	ND	B. Ciullo
	ELISA-Immunoassay	Phencyclidine	ND	B. Ciullo
	LC/MS	Designer Drugs	ND	J. Lintemoot
	Marijuana-GC/MS	11-nor-Delta-9-Carboxy-THC, Total	30 ng/mL	C. DalChele
	Marijuana-GC/MS	Delta 9-Tetrahydrocannabinol (THC), Total	10 ng/mL	C. DalChele

10/19/14

**Legend:**

mg/dL	Milligram per Deciliter	PP	Presumptive Positive
g	Grams	QNS	Quantity Not Sufficient
g%	Gram Percent	ug	Micrograms
Inc.	Inconclusive	ug/g	Micrograms per Gram
mg	Milligrams	ug/mL	Microgram per Milliliter

In accordance with the Department's Evidence Retention Policy, the blood specimen(s) will be retained for one-year and all other specimens for six-months from Autopsy.

Administratively reviewed by:

**Daniel T. Anderson** M.S., D-ABFT-FT, D-ABC  
**Supervising Criminalist II**  
**TOXICOLOGY**

(323) 343-0660 danderson@coroner.lacounty.gov